



# NEUROIMAGING (NI) IN CHILDREN WITH NEURODEVELOPMENTAL DISORDERS (NDDs) IN THE AFRICAN POPULATION

Aleya Remtulla<sup>1</sup>, Emma Eastman<sup>1</sup>, Deepika Goolab<sup>1</sup>, Este Sauerman<sup>1</sup>, Raphaela Itzikowitz<sup>1</sup>, Brigitte Melly<sup>1</sup>, Charles Newton<sup>2</sup>, Amina Abubakar<sup>2</sup>, Elise Robinson<sup>3</sup>, Kirsten A Donald<sup>1</sup>

1. Department of Paediatrics and Child Health, 4th Floor ICH Building, Red Cross War Memorial Children's Hospital and University of Cape Town, Rondebosch, South Africa
2. Neurosciences Unit, Clinical Department, KEMRI-Wellcome Trust Collaborative Research Programme, PO Box 230-80108, Kilifi, Kenya
3. Stanley Centre for Psychiatric Research, Broad Institute of MIT and Harvard, 75 Ames Street, Cambridge, MA 02142, USA



## INTRODUCTION

- NDDs are a group of conditions with onset during the developmental period. They are characterised by developmental deficits which lead to impaired **personal, social, academic and occupational** functioning.
- Pooled prevalence rates for NDDs per 1000 population are as follows; **Asia-pacific 7.5%, Africa 4.4%, Latin America 33.4% and other countries at a cumulative 9.4%**
- **Genetic, environmental and intrinsic factors** are believed to underlie most NDDs and there is a **complex interplay** of different risk factors which may cause functional limitations that define NDDs.
- Neuroimaging (NI) for NDDs, remains a scarce resource and its value in LMICs is unknown.
- It aids in understanding the elements of **timing of insult, type of etiology, degree of abnormality as well as to exclude progressive neurological conditions**.
- Although NI may have a narrow clinical impact, it aids in contributing towards **diagnosis, prognosis and treatment monitoring** for NDDs.
- We investigated the spectrum of NI findings in a clinical population of children with NDDs in South Africa.

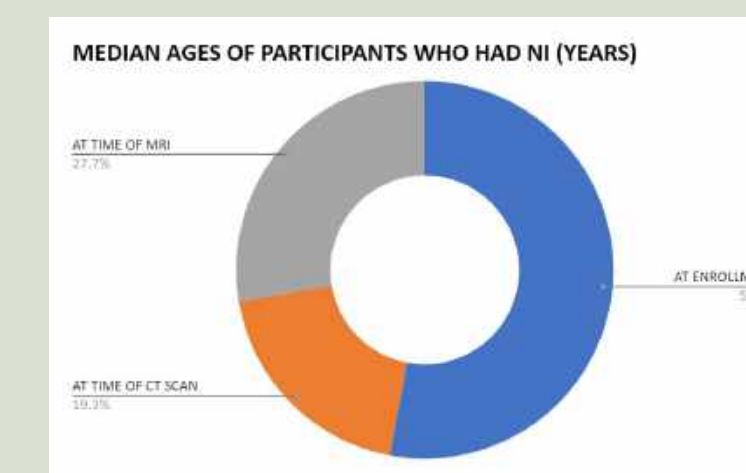
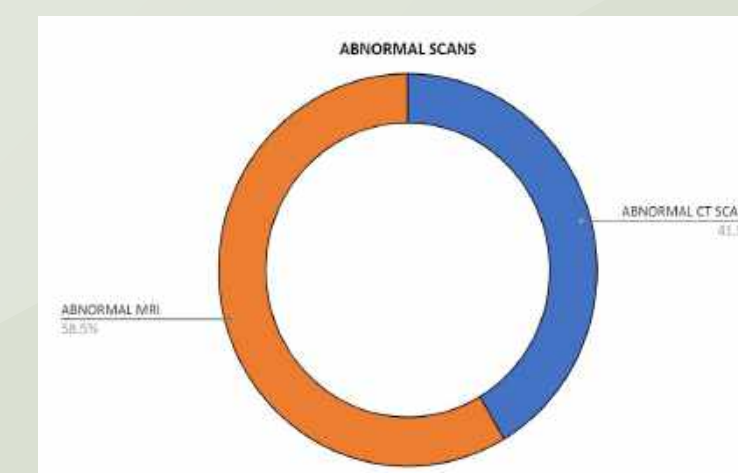
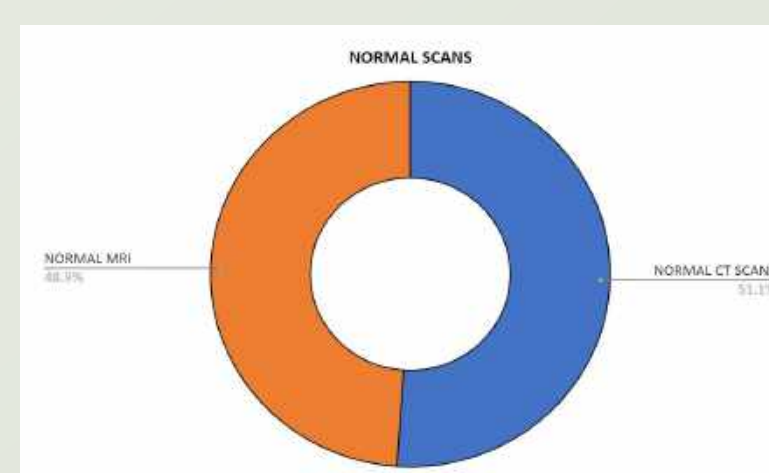
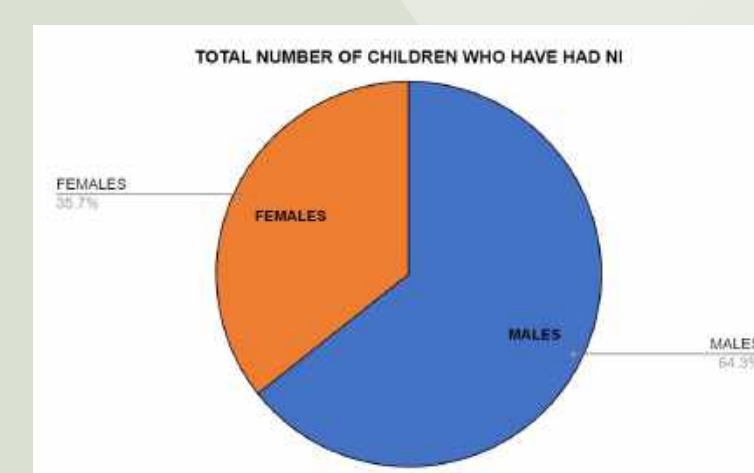
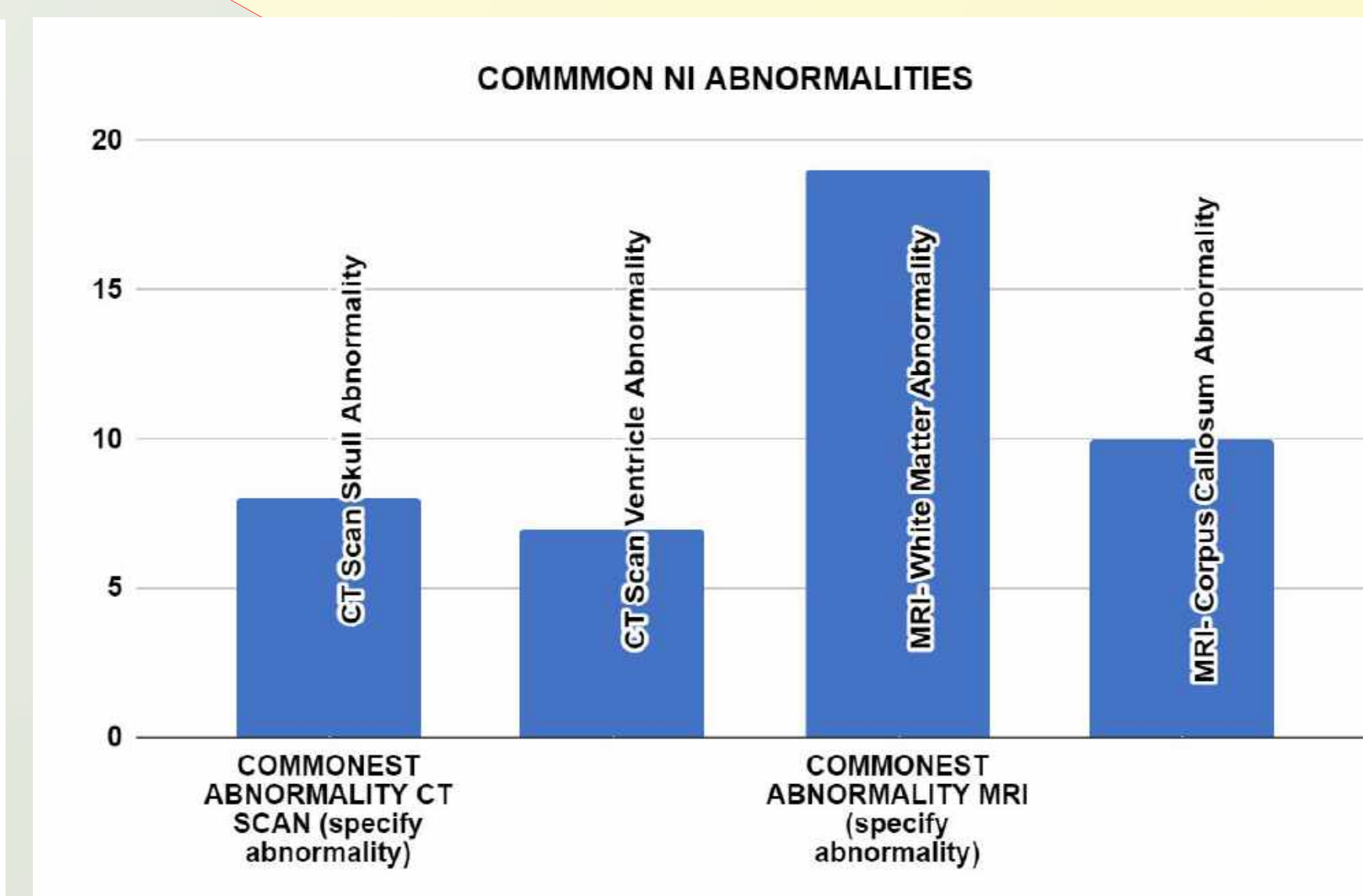
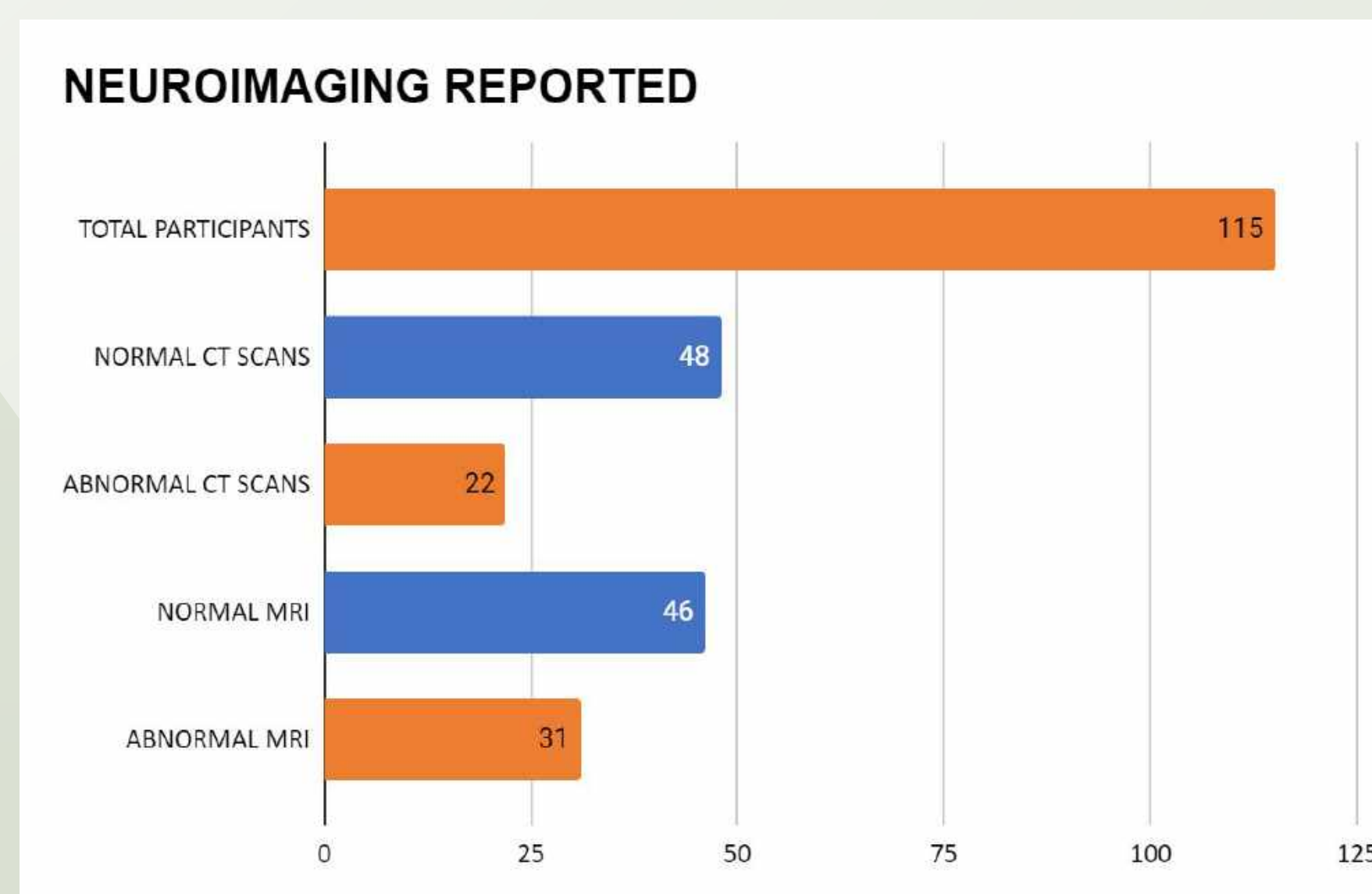
## OBJECTIVES

- To identify what role neuroimaging has contributed towards understanding the **profile, etiology and management** of NDDs in a clinical population.

## MATERIALS AND METHODS

- A **retrospective case research design**
- Embedded in a much larger study called the **NeuroDev study** (the South African arm), a project exploring **genetic variation** amongst children with NDDs in African populations.
- **Clinical information** regarding aetiology, management and NI findings were collected from records of children (**cases only**) attending a tertiary developmental clinic over the period of three years (August 2018-August 2021).
- The clinical records were obtained from the NeuroDev study database- used to identify the **indication** of the NI studies- describing the **range of NI findings and clinical outcomes** of these children.
- NI findings were categorised according to the **most commonly affected parts of the brain**.
- The scans had been individually reported by **specialist paediatric neuro-radiologists**.
- **Secondary data analysis** was conducted and the NI information collected is that which is part of standard clinical protocols in a state project.

## RESULTS (preliminary)



## CONCLUSION

- Preliminary results show **non-specific abnormalities of cerebral white matter** (especially corpus callosum) on brain MRI as the most common pattern in our cohort.
- This was in keeping with several studies which link such findings to an array of NDDs whose exact aetiology remains **unidentified for >50%** of the cases.
- NI may be of value in understanding underlying regions of the brain implicated -or particularly vulnerable to processes- resulting in functional developmental disorders.

## REFERENCES

Fieggen KJ, Investigating developmental delay in South Africa: A pragmatic approach. South African Medical Journal. 2019;109(4); Solomon RS, Early Neurodevelopmental Outcomes After Corrective Cardiac Surgery In Infants. Indian Pediatr. 2018;55(5):400-4; Mithyantha R, Current evidence-based recommendations on investigating children with global developmental delay. Arch Dis Child. 2017;102(11):1071-6; Anderson AN, Neuroimaging in Psychiatry and Neurodevelopment: why the emperor has no clothes. Br J Radiol. 2019;92(1101):20180910.

## ACKNOWLEDGEMENTS

1. Supervisor and mentor Prof Kirsten Donald
2. Funding from African Paediatric Fellowship Program (APFP)
3. Funding from University of Cape Town (UCT)- Department of Paediatrics and Child Health
4. NeuroDev Team for data collection