Relationship Between the Level of Gross Motor Function and Magnetic Resonance Imaging Findings in Children with Cerebral Palsy in a Tertiary Care Hospital

Sanjida Ahmed, Kanij Fatema, Gopen Kumar Kundu, Syeda Tabassum Alam, Rebecca Sultana
Nahid Neela, Sadia Sultana, Zannatul Ferdouse, Bikush Chandra Paul, Krishna Mohon Poddar, Shaheen Akhter

ICNC 2022
17th INTERNATIONAL CHILD NEUROLOGY CONGRESS
ANTALYA, TURKEY | OCTOBER 3-7, 2022

Abstract:
Aims: Assessment of the relationship between the level of gross motor function and MRI of brain findings among the children with cerebral palsy.

Methods: This cross-sectional study was carried out at the department of Pediatric Neurology, BSMMU, Dhaka, Bangladesh. The duration of the study was 12 months. All the CP cases who met the selection criteria were enrolled. Detailed history taking and physical examination was done. The gross motor functions of all patients were evaluated according to GMFCS E&R. MRI of brain was done in all the patients and reports were evaluated by qualified radiologists and cross checked by assigned pediatric neurologists. MRI findings were classified as maldevelopment, cortical and subcortical gray matter lesion, periventricular white matter injury, basal ganglia lesion, normal and other findings.

Results: A total of 45 children with CP were included in this study. Mean age of the children was 4.73 (± 3.17) years.
Functionally, majority patients (26.7%) were in GMFCS level IV. MRI findings were abnormal in 35 (77.78%) cases. Most common abnormal findings were cortical and subcortical grey matter lesions 22(48.9%). This study revealed that cortical and subcortical gray matter lesions were significantly associated with higher level of GMFCS (IV-V) (p = 0.038) and maldevelopment of brain was also significantly associated with severely functionally impaired children (GMFCS) (IV-V) (p = 0.01).

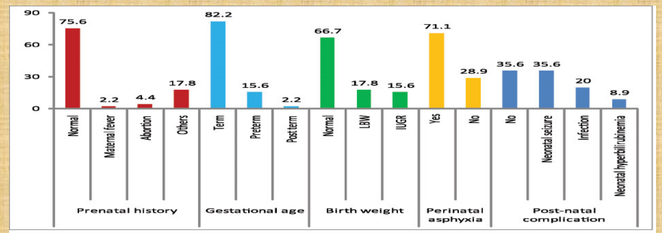

Figure I: Maternal and natal history of the study subjects

Table I : Distribution of the study patients according to topographic type of CP (N=45)

Type of CP	Frequency (n)	Percentage (%)
Spastic Hemiplegia	10	22.2
Spastic Diplegia	5	11.1
Spastic Quadriplegia	15	33.3
Dyskinetic	4	8.9
Ataxic	3	6.7
Mixed	8	17.8

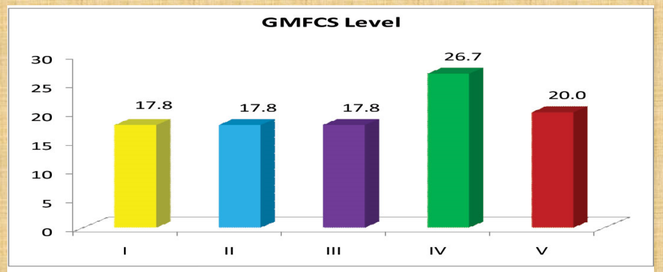

Figure II: Distribution of the study patients according to GMFCS level

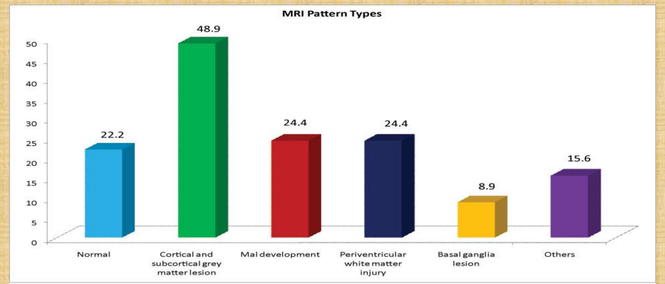

Figure III: Distribution of the CP children according to MRI findings

Table II: Relation of GMFCS level with MRI findings of study subjects (N=45)

MRI findings	GMFCS level					p-value
	I	II	III	IV	V	
Normal	5 (50.0)	3 (30.0)	1 (10.0)	1 (10.0)	0 (0.0)	0.012*
Cortical and subcortical grey matter lesion	2 (9.1)	3 (13.6)	3 (13.6)	6 (27.3)	8 (36.4)	0.077
Mal development	0 (0.0)	0 (0.0)	1 (9.1)	6 (54.5)	4 (36.4)	0.017*
Periventricular white matte injury	1 (9.1)	2 (18.2)	2 (18.2)	5 (45.5)	1 (9.1)	0.491
Basal ganglia lesion	2 (50.0)	0 (0.0)	0 (0.0)	1 (25.0)	1 (25.0)	0.382
Others	0 (0.0)	2 (28.6)	2 (28.6)	2 (28.6)	1 (14.3)	0.608

Table III: Relation of severity of CP with MRI findings of study subjects(N=45)

MRI findings	Severity		p-value
	Mild/moderate (GMFCS I-III)	Severe (GMFCS IV-V)	
Normal	9 (90.0)	1 (10.0)	0.012*
Cortical and subcortical grey matter lesion	8 (36.4)	14 (63.6)	0.038*
Mal development	1 (9.1)	10 (90.9)	0.01*
Periventricular white matter injury	5 (45.5)	6 (54.5)	0.547
Basal ganglia lesion	2 (50.0)	2 (50.0)	1.000
Others	4 (57.1)	3 (42.9)	1.000

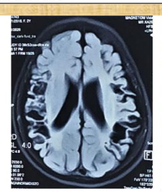
Appendix-I: Multicystic encephalomalacia on axial view.

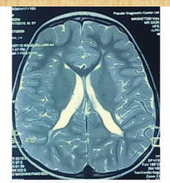
Appendix-II: T2 weighted image on axial view showing Periventricular leukomalacia.

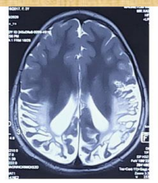

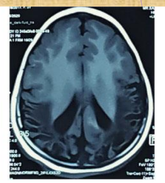
Appedix-III: Multicystic encephalomalacia with occipital predominence on axial view.

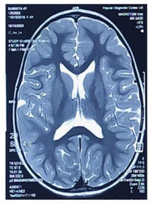
Appendix- IV: Normal MRI on axial view.

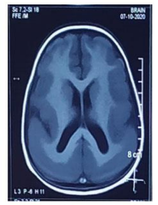
Appendix-V: lissencephaly with classic figure of 8 appearance with smooth outer surface of the cerebral cortex on axial view.

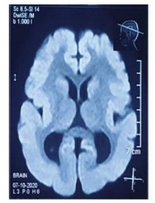

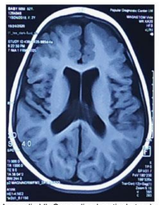
Appendix-VI: Generalized cortical atrophy with temperoparietal predominence.


Appendix-VII: Focal atrophy with gliotic change on left parieto occipital region involving cortex and white matter on axial view.

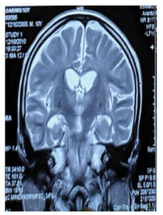
Appendix-IX: Bilateral hippocampal sclerosis on coronal view.

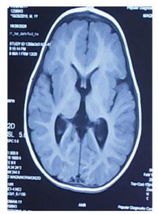
(A)

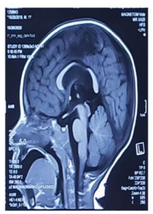
(B)

Appendix-X: Partial agenesis of Corpus callosum on axial (A) and Sagital view (B).

Conclusion: A significant relationship was found between gross motor function and MRI findings of children with CP. This finding indicated that more severe motor impairment was associated with cortical and subcortical gray matter lesions and maldevelopment of brain.

Department of Pediatric Neurology, IPNA, BSMMU